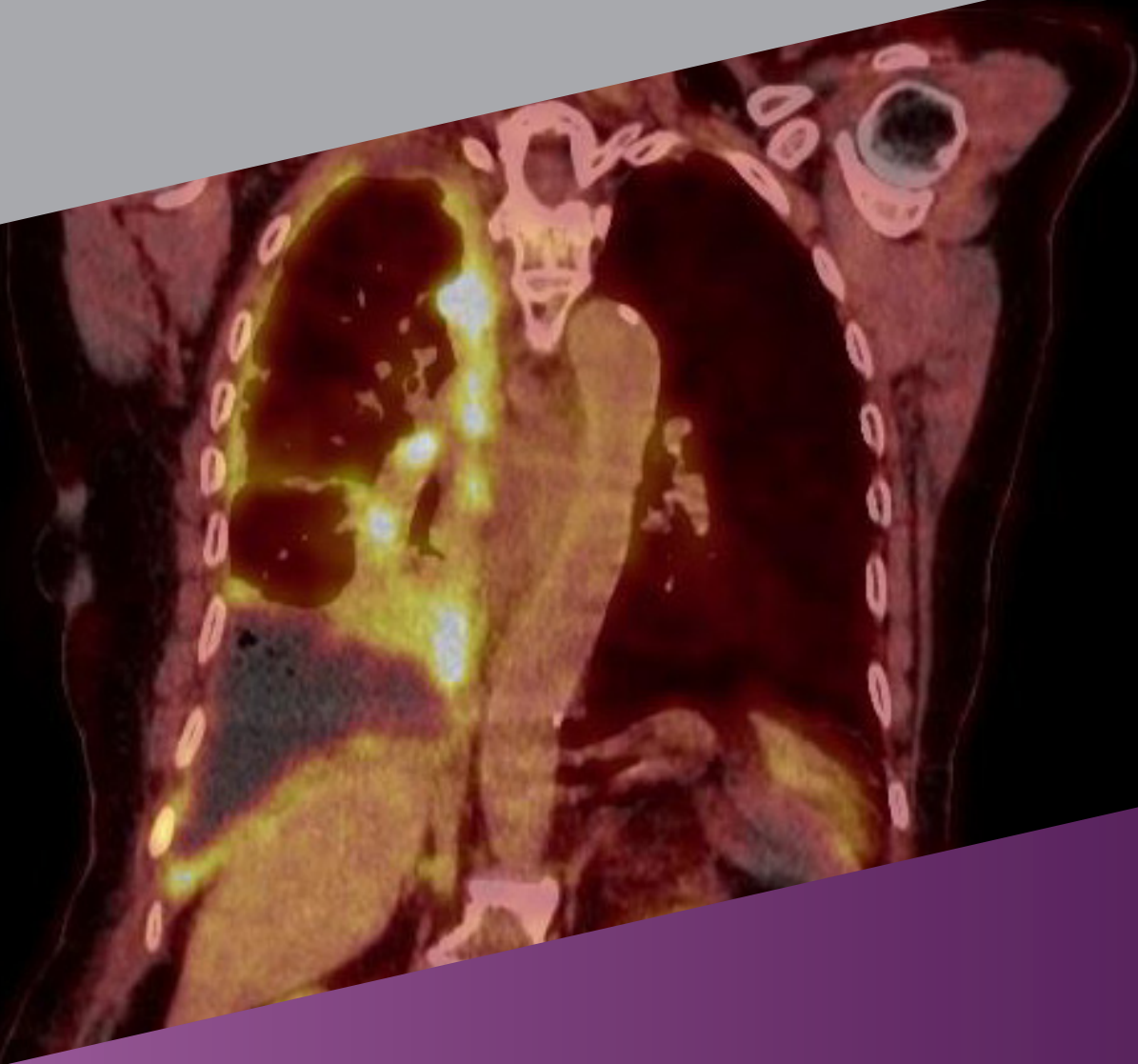




PET/CT OF LUNG



Prepared By:

- Dr.Kalantari.F MD,IBNM
- Dr.Bastami.M MD,IBNM
- Dr.Rezaie.A MD,IBNM

Review

The main cause of cancer related to mortality worldwide is the lung cancer
And it is the second most common type of cancer.

Assessment of suspected lung cancer included morphological and functional imaging including X-ray and CT of thorax, ¹⁸FDG-PET/CT, bone scintigraphy and somatostatin receptor scintigraphy.

Indication

- Morphological and functional Characterization of pulmonary nodules or masses for TNM staging
- Screening for metastases that might not be detected by CT alone
- Radiotherapy planning
- Restaging lung cancer following treatment
- Offer insight into histology of a lesion under investigation
- Facilitate to differentiate synchronous primary tumors from metastatic disease
- Prognostic information gathered with CT

T Staging

CT is an important modality for T Staging assessment.

- PET/CT significantly improves T staging & provides crucial information on mediastinal infiltration and chest wall invasion as well as the differentiation between tumor and post-obstructive atelectasis.
- PET/CT can allow a more detailed characterization of pleural effusions.

N Staging

CT is most widely used technique for N Staging even smaller lymph nodes can reveal lung cancer stage progression.
Functional scans can have greater sensitivity for N staging.

¹⁸FDG-PET/CT have low PPV depends on population characteristic, endemic granulomatous disease and occupational-related lung disorders can lower the PPV of ¹⁸FDG-PET/CT.

Nodal sites that are typically inaccessible to mediastinoscopy such as aortopulmonary window, anterior mediastinum and posterior subcarinal nodes can be shown on ¹⁸FDG-PET/CT.

¹⁸FDG-PET/CT is best non-invasive modality for the detection of nodal metastasis. However, mediastinoscopy is still the gold standard in the status of uncertainty.

M Staging

Metastatic disease is present at the time of diagnosis in nearly half of all cases.

Metastatic disease in NSCLC demonstrates preferences for brain, bone, liver and adrenal.

M staging included CT scans of chest and upper abdomen.

In high stages disease (IIIA or IIIB) bone scintigraphy and brain imaging (CT or MRI) should perform.

Pearls and Pitfalls:

- Adrenal masses present as initial finding in up to 20% of all patients with NSCLC; for the assessment of adrenal masses 18FDG-PET/CT has high sensitivity & specificity.
- The most widely adopted imaging tool for diagnosis metastatic bone involvement in patients with NSCLC is 99mTc scintigraphy.
- Due to high physiologic brain uptake 18FDG-PET/CT had limited specificity but 11-methionine offset this limitation.
- MRI of brain have greater accuracy than 18FDG-PET/CT.
- In preoperative phase 18FDG-PET/CT can reduce the number of patients required to thoracotomy or other futile interventions.

Radiation & Chemotherapy Planning

75% of all NSCLC benefits from radiotherapy in their treatment

The higher diagnostic accuracy of ¹⁸F-FDG-PET/CT improved radiotherapy precision by preventing mistargeting and unnecessary irradiation of adjacent structures Unreliable in the restaging of patients

- ¹⁸F-FDG-PET/CT after neoadjuvant chemotherapy and the pathological confirmation is still needed.

SCLC most aggressive form of lung cancer and account 10-15% of all lung cancer cases

Despite SCLC is chemosensitive in early stages patients will experience recurrences.

Limited disease confined to one hemithorax, mediastinum and supraclavicular lymph nodes. All other presentations including pleural effusion are categorized as extensive disease.

The usefulness of ¹⁸F-FDG-PET/CT imaging in SCLC staging has been validated and lead to therapeutic modifications and correct ¹⁸F-FDG-PET/CT based up or down staging.

Targeted volume during radiotherapy could be more precisely outlined by 18FDG-PET/CT.

In case of suspected CNS involvement methionine-PET and MRI are preferable.

¹⁸F-FDG-PET/CT imaging have the capacity of treatment response assessment (most tumors shows functional changes before anatomical changes).

¹⁸F-FDG-PET/CT can detect early stage disease as well as residual disease in scar tissue or other unsuspecting structures.

There is a positive relationship between SUVmax values and overall survival rates in SCLC.

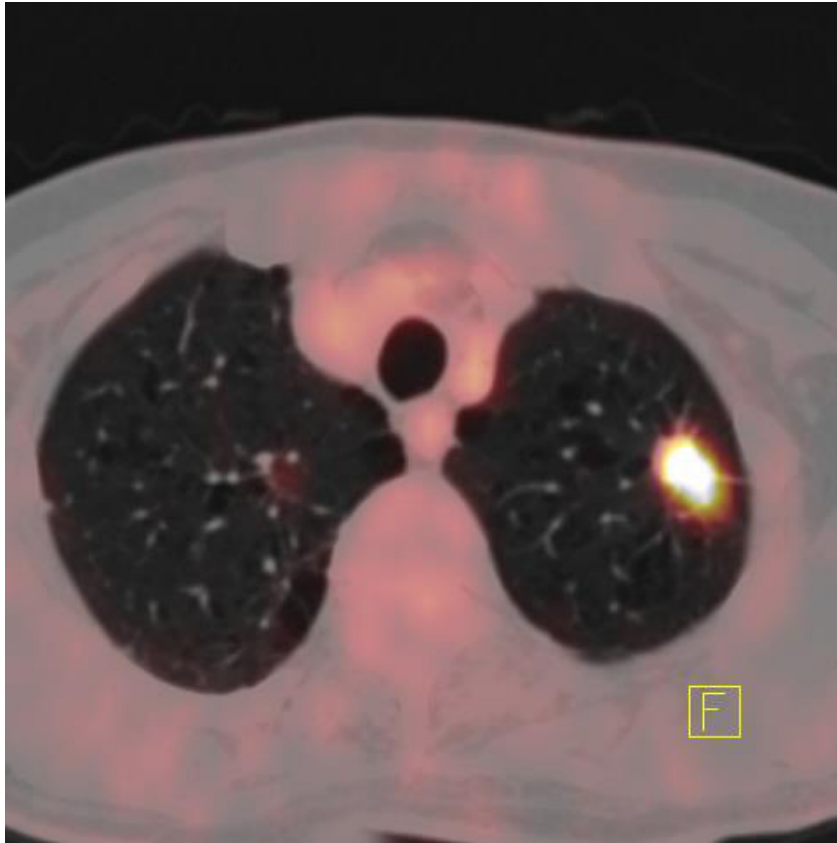
SPN

PET CT can provide functional and anatomical data.

Many early stage lung cancers present as SPN as Single lesion <3cm.

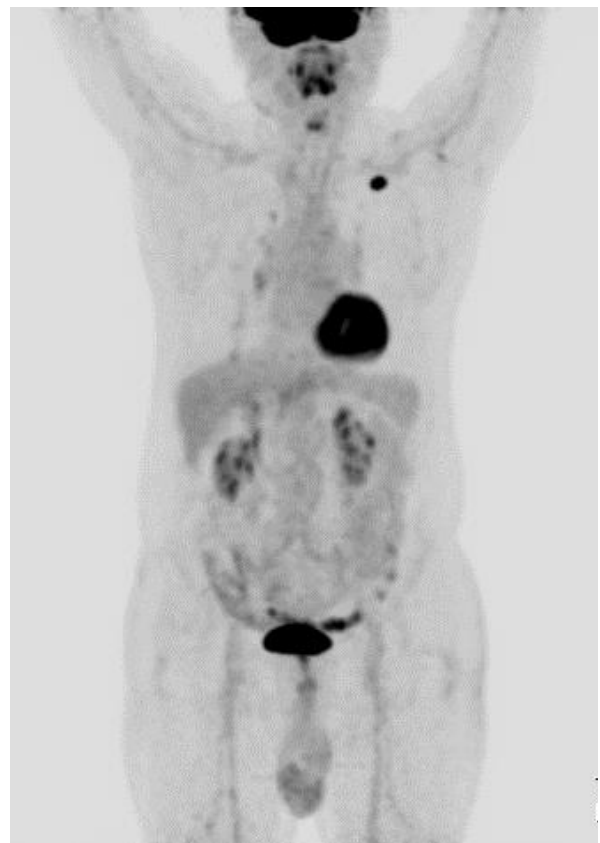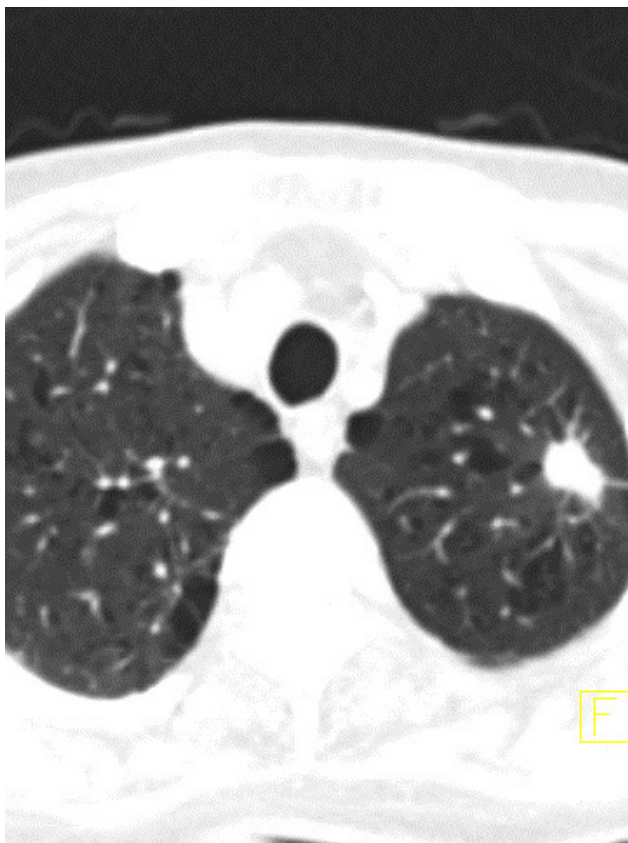
According to American College of Chest Physicians (ACCP) guidelines 18FDG-PET/CT is advisable for lesions > 8mm in patients at low to moderate risk for malignancy.

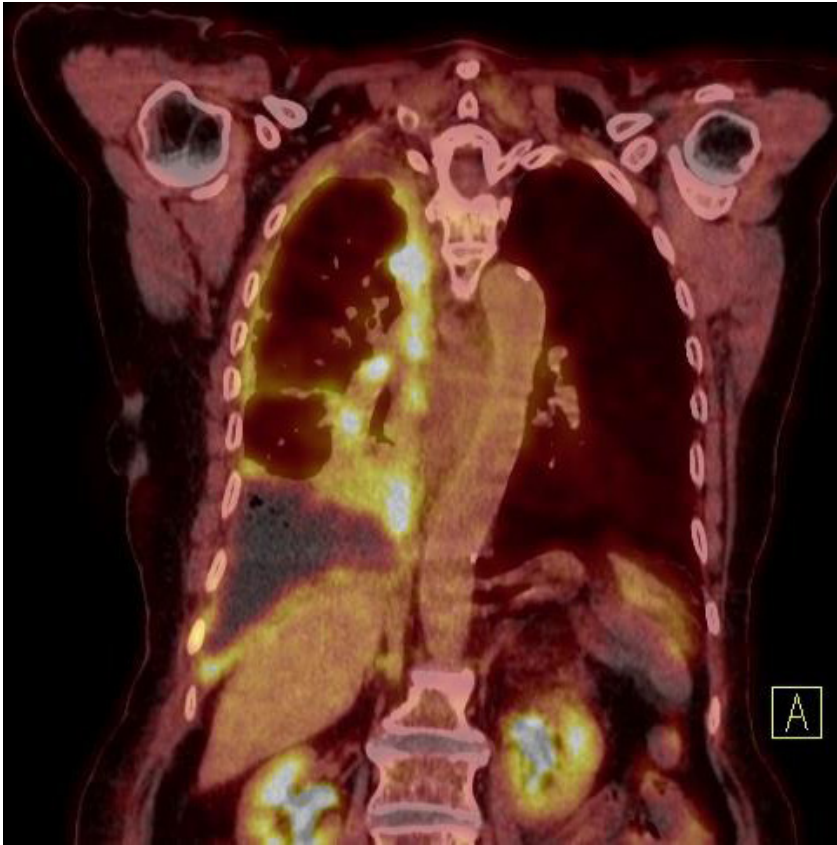PET /CT could benefit patients at high risk for malignancy by evaluating local extent and distant metastases.



Case 1:

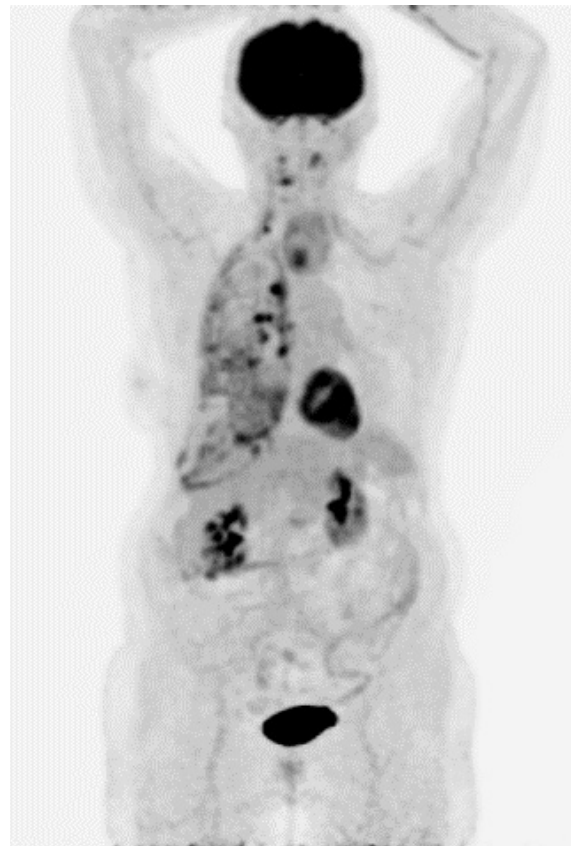
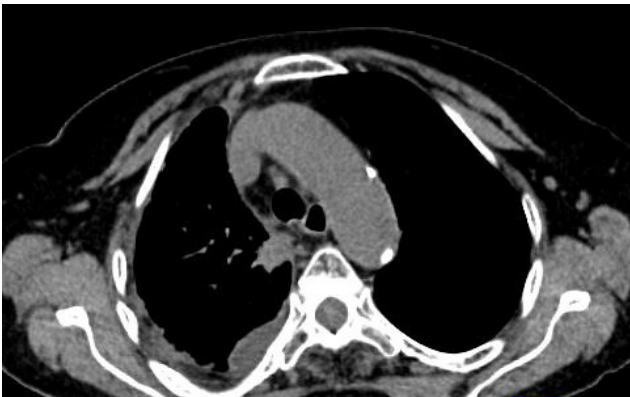
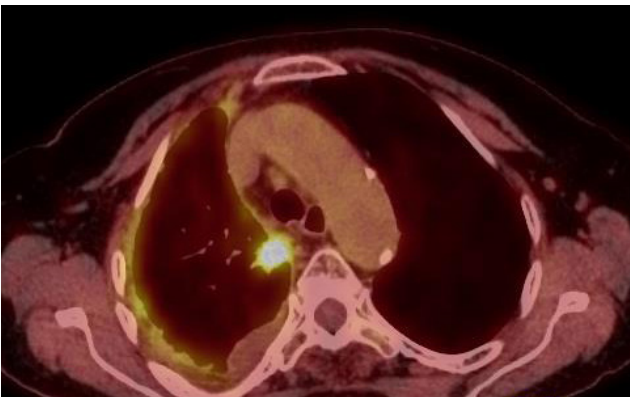
70years old man with incidental finding of a pulmonary nodule detected on a CT study for pneumothorax after ICD placement. It was spiculated and patient had a history of smoking. The SPN was FDG avid on PET/CT study and pathology was squamous cell carcinoma.

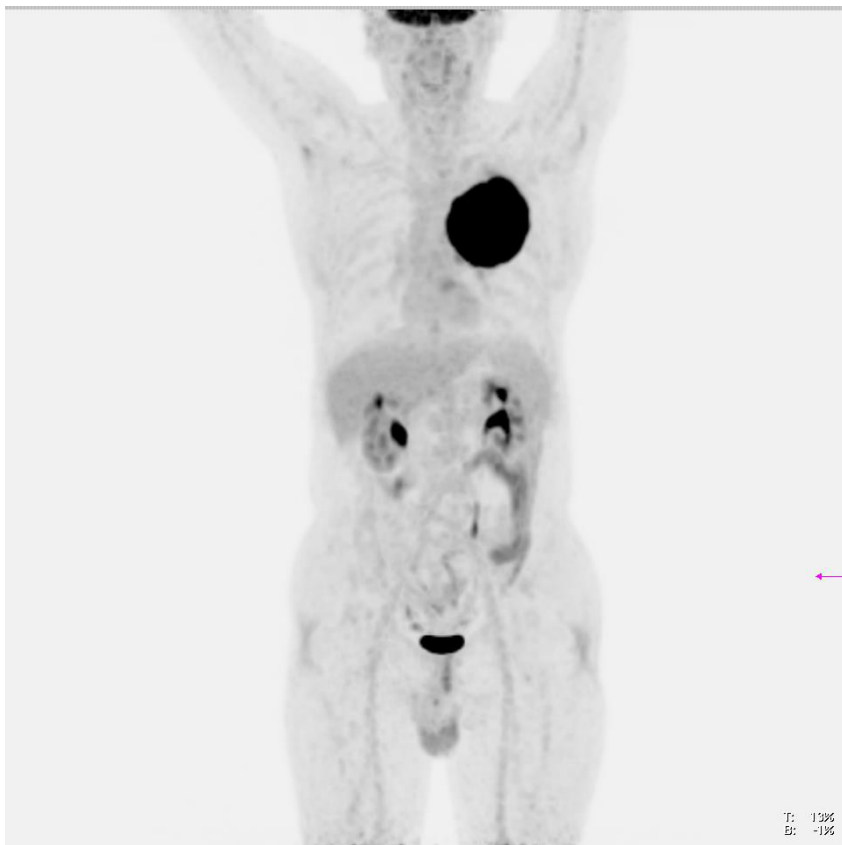




Case 2:

82-year-old man with dyspnea and malignant pleural effusion. On PET-CT study pseudomesothelioma appearance was detected and there was also FDG avid pulmonary nodule, in the posterior segment of the right upper lobe which is most likely consistent with primary malignancy. The pathology was adenocarcinoma.



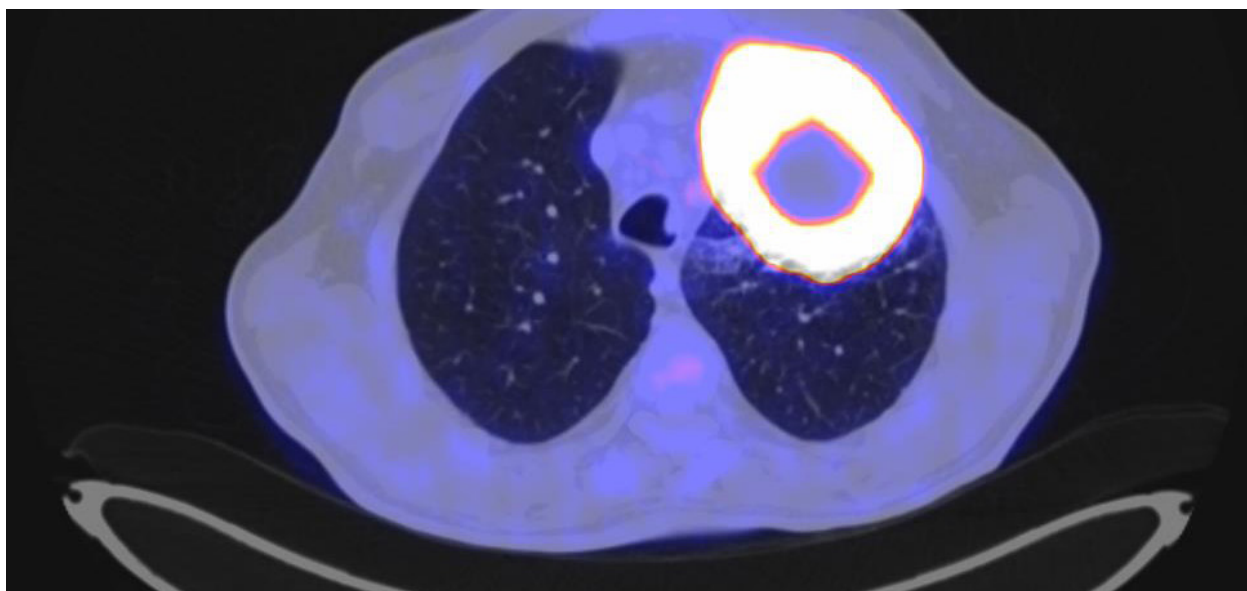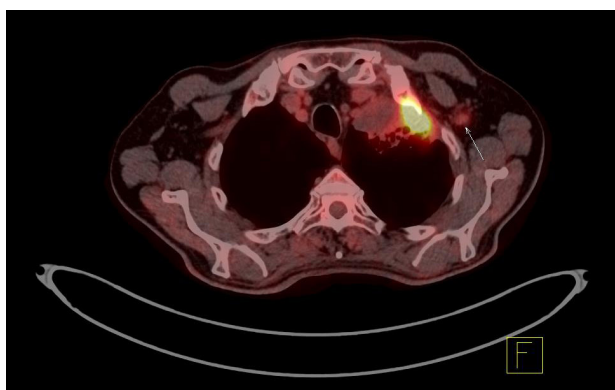
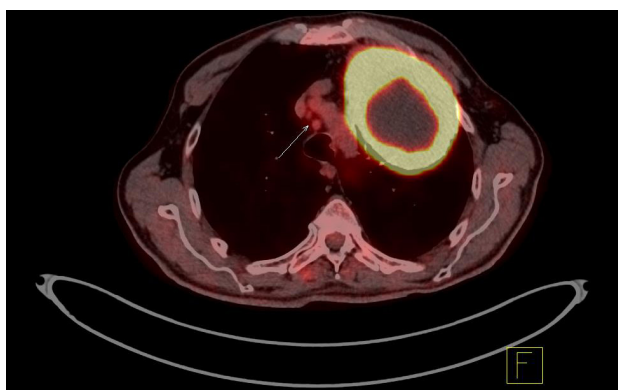


Case 3:

The patient is 65 years old male referred for staging of lung squamous cell carcinoma.

Large, intensely FDG avid left upper lobe pulmonary mass with central necrosis and invasion to chest wall and right anterolateral 2nd rib is seen.

There is also evidence of multiple thoracic lymph node metastases.



References:

- Johnson, A., Norman, R., Piccolo, F. et al. The optimal timing of FDG-PET/CT in non-small cell lung cancer diagnosis and staging in an Australian centre. *BMC Pulm Med* 21, 209 (2021). <https://doi.org/10.1186/s1289001564--021-w>
- Asha Kandathil, Fernando U. Kay, et al. Role of FDG PET/CT in the Eighth Edition of TNM Staging of Non-Small Cell Lung Cancer. *RSNA*, 2018. Vol. 38 (7) <https://doi.org/10.1148/rg.2018180060>
- Mohsen Beheshti, MD, Werner Langster MD, Alireza Rezaee MD et al PET/CT in cancer an inter disciplinary approach to individualized imaging 2018
- Hochegger B, Alves GR, Irion KL, et al. PET/CT imaging in lung cancer: indications and findings. *J Bras Pneumol*. 2015;41(3):264274-. doi:10.1590/S180637132015000004479-
- Kitajima K, Doi H, Kanda T, Yamane T, Tsujikawa T, Kaida H, Tamaki Y, Kuribayashi K. Present and future roles of FDG-PET/CT imaging in the management of lung cancer. *Jpn J Radiol*. 2016 Jun;34(6):38799-. doi: 10.1007/s116042-0546-016-. Epub 2016 Apr 27. PMID: 27121156.
- Ambrosini V, Nicolini S, Caroli P, Nanni C, Massaro A, Marzola MC, Rubello D, Fanti S. PET/CT imaging in different types of lung cancer: an overview. *Eur J Radiol*. 2012 May;81(5):9881001-. doi: 10.1016/j.ejrad.2011.03.020. Epub 2011 Mar 31. PMID: 21458181.



Address: Khatam PET/CT center, Khatam ol
Anbia hospital, Rashid Yasemi St. , Vali- Asr Ave.,
Tehran, 1996835911, Iran.
Tel : +98 21 83557080 - +98 21 83557070

www.petctkhatam.ir